



HISTOLOGICAL SUBTYPES OF HEPATOCELLULAR CARCINOMA DIAGNOSED AT THE UNIVERSITY TEACHING HOSPITAL, LUSAKA, ZAMBIA.

Steward Mudenda^{1*}, Trevor Kaile¹, Marah Simakando¹, Zifa Ngwira¹, Julius Peter², Clemence Marimo³, Derick Munkombwe⁴, Webrod Mufwambi⁴, Chichonyi Aubrey Kalungia⁴, Fred Fredrick Bangara⁵, and Christopher Newton Phiri⁶

¹Department of Pathology and Microbiology, School of Medicine, University of Zambia, Lusaka, Zambia.

²Department of Pathology and Microbiology, University Teaching Hospital, P/Bag: Rw 1X Lusaka, Zambia.

³School of Medicine, P.O Box 34625, Cavendish University Zambia, Lusaka, Zambia.

⁴Department of Pharmacy, School of Health Sciences, P.O Box 50110, University of Zambia, Lusaka, Zambia.

⁵University Research Company Centre for Human Services, Lab Project, Amina House, Off Chilambula Road, Lilongwe, Malawi.

⁶Faculty of Medicine, P.O Box 31909, Lusaka Apex Medical University, Lusaka, Zambia.

Abstract: Hepatocellular carcinoma (HCC) is the most common form of primary hepatic tumour which develops from hepatocytes and is the 5th most common cancer worldwide. A greater burden of HCC occurs due to hepatitis B virus (HBV) and hepatitis C viruses (HCV) which are endemic in regions that are mostly resource constrained sub-Saharan Africa. HCC may also occur due to exposure to aflatoxin B1 and chronic alcoholism. This study was carried out to determine the distribution of HCC subtypes at the University Teaching Hospital in Lusaka, Zambia.

Aim: To determine the distribution of the histological subtypes of hepatocellular carcinoma across all ages and sex groups at the University Teaching Hospital, Lusaka.

Materials/Methods: This was a retrospective cross-sectional study that was conducted at the University Teaching Hospital (UTH) from February 2016 to July 2016. These were tissues diagnosed as HCC from January 2012 to December 2015. Seventeen archival formalin-fixed paraffin embedded (FFPE) liver biopsy specimen blocks were obtained, sectioned, re-stained and examined histologically. Tissues were cut for histological analysis using a microtome. Haematoxylin and Eosin staining was done on the slides to confirm HCC status. Classification of HCC was done according to standard World Health Organization criteria. The results were matched for age and sex to detect any similarities and differences. Data was analyzed using IBM SPSS version 20.0 for windows. Fisher's exact test with a p-value of less than 0.05 was used to indicate statistical significance of the results.

Results: Out of the 17 cases of HCC examined, 9/17 (52.9%) of the cases occurred in people below the age of 50 years and was commonly diagnosed in men 12/17 (70.6%) than in women 5/17 (29.4%). The histological subtypes of HCC reported in this study were trabecular pattern 9/17 (52.9%), pseudo glandular pattern 4/17 (23.5%), solid pattern 2/17 (11.8%), diffuse pattern 1/17 (5.9%), and fibro lamellar pattern 1/17 (5.9%).

Conclusion: HCC was found to occur more commonly in males between the ages of 21-40 years old. The trabecular histological subtype was the predominant pattern of HCC in our patients at the University Teaching Hospital in Zambia.

Keywords: Hepatocellular carcinoma, hepatic tumour, histological subtypes, Zambia.

Introduction: Hepatocellular carcinoma (HCC) is the most common form of primary hepatic tumour which develops from hepatocytes and is the 5th most common cancer worldwide [1]. The highest number of cases of this disease occurs in resource-constrained regions of the world with the highest occurrence in South East Asia and sub-Saharan Africa [2]. This study was carried out to determine the distribution of the histological subtypes of hepatocellular carcinoma across all ages and sex groups at the University Teaching Hospital, Lusaka.

HCC is the third leading cause of cancer deaths worldwide [3]. According to data reported by the GLOBOCAN project of the IARC (International Agency for Research on Cancer), in 2012 the global prevalence of primary hepatic tumors in males was 7.5% and 3.5% in females, a number of 782,000 cases, ranking sixth among all cancer types and mortality was 746,000 death cases, ranking second regarding global cancer mortality rate. Therefore, in 2012 there were 554,000 male patients diagnosed with primary malignant hepatic tumors worldwide, out of whom 521,000 died. With regard to female patients, there were 224,000 death cases out of the 228,000 new cases diagnosed as primary malignant hepatic tumors [4].

HCC represents the main complication of cirrhosis, and shows a growing incidence worldwide related to the increased prevalence of the various risk factors of chronic liver diseases, such as hepatitis infection with HBV and HCV, cirrhosis, and more recently fatty liver diseases which are mostly associated with metabolic syndrome [5]. Other aetiological factors implicated in pathogenesis of HCC

include exposure to aflatoxin B1, chronic alcohol consumption, non-alcoholic steatohepatitis, and dietary iron overload [6]. Liver cirrhosis is the common end-point of most liver diseases and may co-exist with HCC [7]. Although very rarely detected, intra-hepatic cholangiocarcinoma (ICC) is the second most common primary hepatic tumour [8]. In very rare cases, in less than 1% of the cases, HCC may occur simultaneously with ICC [9].

According to the World Health Organization (WHO) classification criteria, HCC presents with the following subtypes; trabecular pattern, pseudo glandular (acinar) pattern, solid pattern, fibro lamellar pattern, clear cell pattern, scirrhous pattern, diffuse pattern, steatohepatic pattern, transitional liver cell tumor pattern, sarcomatoid pattern, undifferentiated carcinoma pattern, combined HCC-ICC pattern, and lymphoepithelioma-like HCC pattern [10]. The WHO emphasizes that these subtypes of HCC play a more significant role in diagnosis of HCC than in the indication of prognosis of HCC.

Repeated cycles of cell death and regeneration, as occurs in chronic hepatitis from any cause, are important in the pathogenesis of HCC. Preneoplastic changes such as hepatocyte dysplasia can result from point mutations in selected cellular genes, loss of heterozygosity in tumour suppressor genes, DNA methylation changes, and constitutive expression of hepatocyte growth factor (HGF) and transforming growth factor alpha (TGF- α). These changes and possibly the effect of some viral proteins act to further stimulate the replication of hepatocytes [11].

HCC clinically present in a variety of ways depending on the size, stage, and type of the hepatic tumor [12]. HCC may be discovered on medical imaging equipment (often by accident) or present themselves symptomatically as an abdominal mass causing hepatomegaly, ascites, abdominal pain, back pain, itching, jaundice,

For Correspondence:

freshsteward@gmail.com.

Received on: December 2016

Accepted after revision: December 2016

Downloaded from: www.johronline.com

nausea, weight loss, fever, or abnormal liver function tests[13].

A number of investigations can be performed for the diagnosis of HCC. These investigative techniques include imaging modalities such as sonography (ultrasound), Computed Tomography (CT), and Magnetic Resonance Imaging (MRI) [14]. Other investigations that can be done include haematologic tests to check for tumor markers which are chemicals that are found in blood of people with HCC; such as alfa-fetoprotein (AFP) [15]. Elevated levels of serum AFP are found in 50% to 75% of patients with HCC. A fine needle aspiration (FNA) can also be done to investigate hepatic tumors. True cut liver biopsies may be used to identify or exclude possible aetiologies for physical or laboratory abnormalities. True cut biopsies provide a better insight for diagnosis of suspected HCC[16].

The prognosis of HCC is dependent on the size of the tumour, the stage, and the histological subtypes. High-grade tumours have a poor prognosis, while low-grade tumours have a good a prognosis and may go unnoticed for many years. The prognosis of HCC is good when the tumour is diagnosed in its early stage. The prognosis is poor when the HCC is diagnosed in its late stage because even the treatment modalities are limited. The usual outcome is poor, for instance only 10-20% of HCC can be removed completely using surgery [17].

In Zambia, no study has ever been done to determine the histological subtypes of HCC. This study aimed at investigating the different histological subtypes of HCC diagnosed at UTH in Lusaka, Zambia.

Materials and Methods

Study design and period: This was a retrospective cross-sectional study which involved 17 FFPE liver archival tissue blocks diagnosed with HCC at the University Teaching Hospital in Lusaka, Zambia from January 2012

to December, 2015. This study was conducted from February 2016 to July 2016.

Study site and sampling frame: The study was carried out at the University Teaching Hospital, Lusaka, in the Histopathology and Immunohistochemistry Laboratory, Department of Pathology and Microbiology. In this study, a convenience sampling method was used on 34 FFPE archival tissue blocks which were diagnosed with hepatic tumours between 1st January 2012 and 31st December 2015. Convenience sampling method was used on all the hepatic tumour tissue blocks which were available, accessible, and eligible during the period of the study. From the available, accessible, and eligible hepatic tumour tissue blocks, convenience sampling method was used during the period in this study because of the small sample size.

Determination of histological subtypes of hepatocellular carcinoma: Archival records and FFPE liver tissue blocks were retrieved, labeled, re-sectioned, and stained. Tissues were cut for histological analysis using a microtome. Haematoxylin and Eosin staining was done on the slides to confirm hepatic tumour status. Special stains such as reticulin silver stain, Masson's trichrome, and Periodic Acid Schiff (PAS) stain were also used. The specimens were viewed under a light microscope and classified using resolution power of 400x [18].

Specimen labeling: The labeling was done for each hepatic tumour specimen to which a new identification code was given for confidentiality and easier identification. The letter "H" represented hepatic tumour specimen plus a three digit numbering system that is (000) were used. Therefore, the specimen numbers such as 1, 2, 3, 4, 5, 6, 7, 8, 9 and 10 were labeled as H001, H002, H003, H004, H0005, H006, H007, H008, H009 and H010, respectively.

Specimen sectioning: In the histopathology laboratory, the specimens to be sectioned on the microtome machine were placed face down on

an ice-cold plate for about 20 minutes. Then the water bath was turned on and temperature was set at 37 °C. The paraffin block was placed in the block holder of the microtome machine. The paraffin block advanced closer to the microtome blade.

The dial was set to cut approximately 10µm sections and the blade was set at an angle of 6°. The rough trimming of the paraffin section was done until a complete section was seen in the tissue block. A ribbon was obtained by using a clean section of the blade and was picked by the forceps and then it was transferred to the water bath. To allow the sections to stretch, the ribbon was laid on the water bath for a few seconds. The cut sections were then gently separated and each section was picked on a glass slide. To allow the water to exit the slide and section, the sections were picked at an angle. Before putting the specimen slide on the hot plate, the slide sections were allowed to drain just for a few minutes. The tissue sections were put on the hot plate so as to remove some more water from the tissue section. The glass slides were finally placed in a warm plate for about 15 minutes to help the tissue section adhere to each slide.

Ehrlich's Haematoxylin and Eosin (H and E Stain) Staining: Mounted specimen sections were softened using ethanol and rehydrated so as to facilitate the penetration of the water based H and E stain. The sections were then taken into the water, and were dewaxed in two washes of xylene for 2 minutes each. The sections were then washed in 2 changes of absolute alcohol for 2 minutes each. After that, the sections were washed in water for 2 minutes. Finally, the slides were then stained with Ehrlich's Haematoxylin solution for about 30 minutes. The stained slides were washed in running tap water for about 5 minutes and then differentiated in 1% hydrochloric acid in 70% alcohol (1% acid alcohol) for 15-30 seconds. The stained slides were blued in running tap water for 10 minutes and later counter stained in

1% aqueous eosin for 5 minutes. Lastly, the stained slides were then rinsed in 95% alcohol, dehydrated in 2 changes of absolute alcohol for 2 minutes each, and then cleared in 2 changes of xylene for 2 minutes each.

Cover slipping: In this procedure, the slides were placed on a clean horizontal bench surface and a drop of DPX Mountant was applied to each tissue section at the far end of the slide away from the frosted end in order to preserve the stain. The cover-slip was then gently applied by placing one end of the slip on top of the drop of DPX Mountant at the far end of the slide. Slowly, gently, and carefully, the cover slip was rolled down the side, only using minimal pressure to allow the medium to spread evenly. The slides were later placed flat onto the clean horizontal surface bench for 120 minutes to eliminate bubbles under the cover slip. The slides were removed from the bench after they became dry and were ready for microscopic examination.

Histological classification of hepatocellular carcinoma: Hepatic tumours were classified histologically according to the standard World Health Organization criteria and HCC cases were further grouped into histological subtypes as trabecular, pseudo glandular, solid, diffuse, or fibro lamellar [19].

Data analysis: Data was analyzed using IBM SPSS version 20.0 for windows and Fisher's exact test with a p-value of less than 0.05 was used to indicate statistical significance of the results in prevalence of the histological subtypes of HCC.

Ethical consideration: The research was done under ethical approval by the University of Zambia Biomedical Research Ethics Committee (UNZABREC). Permission to conduct the study was sought from the University Teaching Hospital Senior Medical Superintendent. The samples which were used were archival tissues which came from patients.

Results

General characteristics of the study population

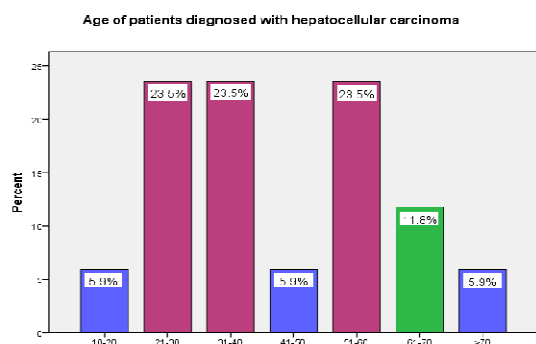


Figure 1: Age distribution

HCC was found to be more prevalent between the ages of 21-40 years with another peak between 51-60 years old. The p-value=0.04.

Sex of patients diagnosed with hepatocellular carcinoma

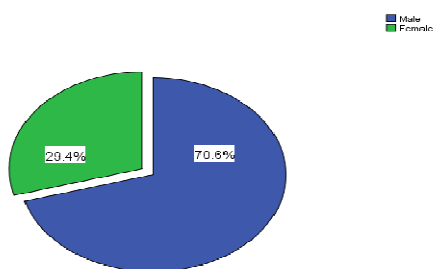


Figure 2: Sex distribution

HCC was found to be more prevalent in males than females with a male to female ratio of 2.4:1. The p-value=0.04

Histological Subtypes of hepatocellular carcinoma

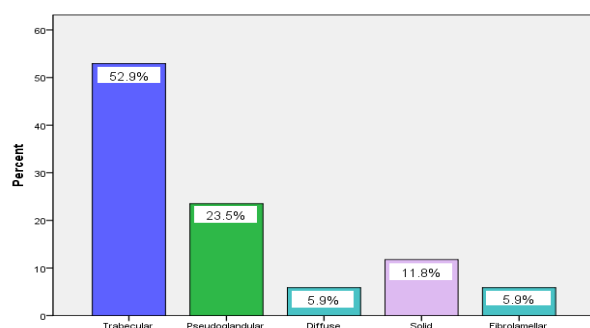


Figure 3: Distribution of Histological Subtypes of Hepatocellular Carcinoma

The trabecular histological subtype of HCC was the most prevalent subtype in our Zambian patients. The subtypes of HCC were not significantly affected by age and sex. P-value=0.4.

Discussion: Hepatocellular carcinoma (HCC) is the most common form of primary hepatic tumour which develops from hepatocytes. HCC is of global concern due to increased morbidity and mortality which occurs as a result of these tumours [20]. HCC accounts for 85-90% of all primary hepatic tumours, with a median survival of less than one year. The highest age HCC incidence rates are reported from countries in Southern Asia such as North/South Korea, China, and Vietnam which are endemic for HBV infections. China alone accounts for about 50% of HCC. Other high-incidence areas include sub-Saharan African countries such as Cameroon and Mozambique. Southern European countries such as Italy and Greece have medium incidence rates of HCC. Intermediate incidence areas include the United Kingdom (UK), United States of America (USA), France, and Germany. Low-incidence areas include Central and Southern America, Europe but excluding the Mediterranean countries, and North America. An increased mortality rate due to HCC has been observed in areas previously considered as low-incidence such as North America, Oceania, and Europe. In these regions, HCV is the commonest aetiological factor of HCC [21].

In this study, we investigated the prevalence of HCC in different age and sex groups. We subtyped HCC using the WHO criteria into trabecular, pseudo glandular, solid, diffuse, and fibro lamellar.

General characteristics of the study population: The age range of patients affected with HCC in this study was 19-79 years. The age range in our study is comparable with the age range of 19-86 years age group in a study which was conducted in Nigeria by Okokwo *et al.* [22]. The high prevalence of HCC and peak age was observed within the age group of 21-40

years in our study. In contrast with the findings of this study, a study in Nigeria by Vhritherhire and colleagues recorded a peak age of 40-50 years [23]. Another study in Taiwan by Sung and colleagues recorded a peak age of HCC in the age group of 41-50 years [24]. The mean age of patients in our study was found to be 43.4 years which was lower but slightly similar with the mean age of 49 years which was recorded in a study that was done in Gambia by Umoh *et al.* [25]. In contrast to our findings, a mean age of 35.8 years was recorded in the Democratic Republic of Congo by Kashala *et al.* [26]. There has been a lot of controversy between age and prognosis of HCC in different studies. A study by Zhang *et al.* [27] in China reported that younger patients had a better prognosis than older patients due to better liver functions in younger patients. In contrast to the finding of Zhang *et al.*, two studies by Cho *et al.* [28] and Shimada *et al.* [29] reported that younger patients with HCC had a poor prognosis because they are exposed to risk factors at an early age and the HCC is usually detected at an advanced stage. HCC affects more males than females as was recorded in this study where 12 (70.6%) cases were males and 5 (29.4%) cases were females. The male to female ratio of patients affected with HCC at UTH was found to be 2.4:1 and is consistent with the global male to female ratio of 2.4:1 recorded by Kew *et al.* [30].

A similar evaluation in sub-Saharan resource constrained regions recorded a male to female ratio of patients affected with HCC as 2.4:1 [31]. In contrast to our findings, in South Africa, HCC showed an increased male to female ratio of 4.4:1 [32]. Another study in the USA by Yang *et al.* [33] recorded a male to female ratio of 3.1:1. All these results show that more males are affected than females. The increased risk of HCC development in Black African males may reflect in part, their higher rate of chronic infection with HBV, approximately twice that of females [34]. Some studies recorded an increase in the male to female ratio because of

increased exposure to aflatoxin B1 than do females [35]. However, this may not be true for our Zambian patients. There are also some differences between the two sexes in the rates as well as the efficiency with which ingested chemical carcinogens are metabolized [36]. Chronic HBV infection and dietary exposure to aflatoxin B1 are known to have a synergistic hepatogenic interaction [37]. Furthermore, dietary iron overload in the Black Africans is another cause of HCC and is more common in males than in females because males consume far larger volumes of the iron-rich home-brewed alcohol and they do not menstruate [38]. Some studies have reported that more males are affected with HCC and have a poor prognosis than women because of the androgens demonstrating a synergistic oncogenic effect with HBV in males with HCC, [39], but not in females, [40]. In addition to this, Fernandez *et al.* [41] and Tavani *et al.* [42] reported that few females were affected with HCC and had a better prognosis than males because estrogen demonstrated a protective role in patients with HCC and hence an improved prognosis in females.

Histological subtypes of HCC: The most common histologically diagnosed subtype of HCC at UTH in Lusaka in our study was the trabecular subtype followed by the pseudo glandular subtype. Our results of histology showed that the trabecular subtype of HCC was the predominant histologically diagnosed subtype of HCC were consistent with studies done in East Africa in Tanzania (47.9%), in Southern Nigeria (49.3%), in (USA) (43%), in Malaysia (73.1%), in Southern Thai (63.3%), and in France (70%) respectively [43, 44, 45, 46, 47, 48]. In contrast to the findings of our study, a study by Khan *et al.* [49] in Bangladesh showed different outcomes which recorded the pseudo glandular subtype of HCC as the predominant subtype (45.3%) followed by the trabecular subtype (39.6%). The results of our study recorded fibro lamellar subtype as the most rarely diagnosed histological subtype of

HCC which is in line with what was recorded in another study in Nigeria by Nzeako *et al.* [50] and a similar study in the USA by El-Serag *et al.* [51]. A study in the USA by Jernigan *et al.* [52] reported different results in which trabecular subtype was the most rarely diagnosed histological subtype of HCC compared to fibro lamellar subtype.

A different study in the USA by Eggert and colleagues recorded fibro lamellar subtype of HCC as the predominant histologically diagnosed subtype of HCC [53]. The distribution of the other subtypes is however different in various studies except for fibro lamellar pattern which consistently occurs rarely. The distribution of HCC seems to be according to geographical locations [54]. The prognosis of HCC may differ geographically due to differences in geographical distribution of the risk factors that are associated with HCC. The prognosis of HCC may be affected because some subtypes of HCC with poor prognosis are predominant in some areas while other subtypes with good prognosis are predominant in other regions. For example, a study by Mayo *et al.* [55] in the USA recorded that fibro lamellar subtype showed the highest median survival age with a good prognosis than other subtypes. Other studies such as a study which was done by Chedid *et al.* [56] reported that the trabecular subtype of HCC had a poorer prognosis than the other subtypes. Hence, the most commonly diagnosed histological subtypes of HCC at UTH tended to have a poor prognosis than the rare subtypes. Therefore, this study may be used as a baseline study for future studies which may improve the prevention, diagnosis and treatment of HCC in Zambia.

Conclusion: HCC was found to affect more males between the ages of 21-40 years old. The trabecular subtype of HCC was the most predominant histological subtype and it occurred more commonly in males than in females. The trabecular subtype of HCC tends to have poor prognosis. We recommend further studies to determine the associated aetiological

and risk factors of this subtype of HCC as a basis for prevention, diagnosis, and treatment.

Acknowledgements: We would like to thank the UTH administration for allowing us use the institution to conduct the study, the UTH histopathology and immunohistochemistry laboratory staff for their support. We would also want to thank University of Zambia (UNZA) School of medicine, UNZA Staff Development Fellow Office for their financial support, and all individuals who made substantial contributions to the success of this study.

References

1. Ferlay J, Shin HR, Bray F, Edwards B, Forman D. Establishment of worldwide burden of cancer in 2008: GLOBCAN 2008. *International Journal of Cancer*. 2010; 127:2893-917.
2. Parkin DM, Ferlay J, Hamdi-Cherif M, Thomas J, Wabinga H, Whelan S.L. Cancer in Africa: Epidemiology and Prevention. *IARC Scientific Publications*. No. 153. Lyon, France. IARC Press; 2003.
3. Gomaa AI, Khan SA, Toledano MB, Waked I, Taylor-Robinson SD. Hepatocellular carcinoma: epidemiology, risk factor and pathogenesis. *World Journal of Gastroenterology*. 2008; 14:4300-4308.
4. Ferlay J, Soerjomataram I, Ervik M, Dikshit R, Eser S, Mathers C, Rebelo M, Parkin DM, Forman D, Bray F. (2012). GLOBOCAN. *Cancer Incidence and Mortality Worldwide-IARC Cancer Base No. 11*, Lyon, France.
5. Nordenstedt H, White DL, El-Serag HB. The changing pattern of epidemiology in hepatocellular carcinoma. *Dig Liver Dis*. 2010; 42:206-214.
6. Kuniholm MH, Lesi OA, Mendy M, Akano A, Sam O, Hall AJ. Aflatoxin exposure and viral hepatitis in the aetiology of liver cirrhosis in the Gambia, West Africa. *Env Health Perpect*. 2008; 116:1553-57.
7. Ishikawa T. Clinical features of hepatitis B virus-related hepatocellular carcinoma.

- World Journal of Gastroenterology*. 2010; 16:2463-2467.
8. Park J, Kim M.H, Kim K.P, Park DH, Moon S.H, Song T.J, Eum J, Lee S.S, Seo D.W, Lee S.K. Natural history and prognostic factors of advanced cholangiocarcinoma without surgery, chemotherapy, or radiotherapy: a large-scale observational study. *Gut Liver*. 2009;3:298-305.
 9. Cao J, Huang L, Liu C, Li J, Zhang X, Shen J, Li J, Lu L, Xu F, Yan J, Wu M, Lau WY, Yan Y. Double primary hepatic cancer (hepatocellular carcinoma and intrahepatic cholangiocarcinoma) in a single patient: a clinicopathologic study of 35 cases. *J Gastroenterol Hepatol*. 2013; 28:1025-31.
 10. Bosman FT, Carneiro F, Hruban R.H, Theise ND. Tumours of the digestive system. *WHO Classification of Tumours*. IARC Press, Lyon. 2010; 217-225.
 11. Kumar V, Abbas AK, Fausto N. Robbins and Cotran Pathological Basis of Disease. Saunders, 7th edition, Philadelphia. 2005; 18:881-899.
 12. Shirine B, Delphine C, Christine N, Marie A.B. Liver Cell Transformation in Chronic HBV Infection. *Oncogenesis and Molecular Virology Unit*, Paris. 2009; 1:630-646.
 13. Tanaka M, Kataya F, Kato H, Tanaka H. Hepatitis B and C virus infection and hepatocellular carcinoma in China. *A review of epidemiology and control measures*. 2011; 6:401- 416.
 14. Malaguarnera G, Paladina I, Giordano M, Malaguarnera M. Serum markers of intrahepatic cholangiocarcinoma. *Disease markers*. 2013; 4:219-228.
 15. Zhao Y, Qiang J, Li C, Guan C. Tumor markers for hepatocellular carcinoma. *Molecular and clinical oncology*. 2013; 4:593-598.
 16. Ingram K, Flora KD, Zaman A, Katz J. Diagnostic Liver Biopsy. *World Journal of Gastroenterology*. 2015; 1-8.
 17. Gorayski P, Thompson CH, Subhashi HS, Thomas AC. Hepatocellular carcinoma associated with anabolic steroid use. *British Journal of Sports Medicine*. 2007; 42:74-75.
 18. Saxena R. Special Stains in Interpretation of Liver Biopsies. *Connection*. 2010; 103:1-12.
 19. Hirohashi S, Ishak KG, Kojiro M. Hepatocellular carcinoma in: Hamilton SR, Aaltonen LA (eds). *World Health Organization Classification of Tumours. Pathology & Genetics of Tumours of the Digestive System*, Lyon, IARC Press. 2000; 159-172.
 20. Ananthkrishnan A, Gogineni V, Saesian K. Epidemiology of primary and secondary liver cancers. *Thieme Medical Publishers*. 2006; 1-17.
 21. El-Serag HB, Rudolph KL. Hepatocellular carcinoma: epidemiology and molecular carcinogenesis. *Gastroenterology*. 2007; 132:2557-76.
 22. Okokwo UC, Nwosu NM, Ikoh C, Okpala OC, Aheneku J.I. The clinical and pathologic features of hepatocellular carcinoma in Nnewi, Nigeria. *Niger J Med*. 2011; 20:366-71.
 23. Vhritherhire RA, Ngbea JA, Ojo BA, Jegede OO, Manasseh A.N, Ayuba MO, Mandong BM. Hepatocellular carcinoma subtypes in North-Central Nigeria: A Histological Review of Liver Biopsies. *British Journal of Medical Research*. 2016; 12:1-8.
 24. Sung JL, Wang TH, Yu JY. Clinical study on primary carcinoma of the liver in Taiwan. *Am J Dig Dis*. 1967; 12:1036-49.
 25. Umoh NJ, Lesi OA, Mendy M, Bah E, Akano A, Whittle H, Hainut P. Etiological differences in demographical, clinical and pathological characteristics of hepatocellular carcinoma in the Gambia. *Liver Int*. 2011; 31:215-21.
 26. Kashala LO, Conne B, Kalengayi MM, Kaponchi Y, Frei PC, Lambert PH. Histopathological features of hepatocellular carcinoma in Zaire. *Cancer*. 1990; 65:130-4.
 27. Zhang W, Sun B. Impact of age on the survival of patients with liver cancer: an

- analysis of 27255 patients in the SEER database. *Oncotarget*. 2014; 6:633-641.
28. Cho SJ, Yoon JH, Hwang SS, Lee HS. Do young hepatocellular carcinoma patients with relatively good liver function have a poorer outcome than elderly patients? *J Gastroenterol Hepatol*. 2007; 22:1226-1231.
 29. Shimada S, Kamiyama T, Yokoo H, Wakayama K, Tsuruga Y, Kasisaka T, Kamachi H, Taketomi A. Clinicopathological characteristics and prognostic factors in young patients after hepatectomy for hepatocellular carcinoma. *World J Surg Oncol*. 2013; 11:52.
 30. Kew MC. Epidemiology of hepatocellular carcinoma in sub-Saharan Africa. *Annals of hepatology*. 2013; 12:173-182.
 31. Jemal A, Bray F, Center MM, Ferlay J, Ward E, Forman D. Global cancer statistics. *CA: A cancer journal for clinicians*. 2011; 61:69-90.
 32. Fujita Y, Kew MC, Takahashi H, Coppins A, Wands JR. Comparison between polyclonal and first and second generation monoclonal radioimmunoassays in the detection of hepatitis B surface antigen in patients with hepatocellular carcinoma. *Hepatology*. 2014; 6:636-639.
 33. Yang D, Hanna LD, Usher J, LoCoco J, Chaudhari P, Lenz JH, Setiawan W, Khoueiry AL. Impact of sex on the survival of patients with hepatocellular carcinoma: A surveillance, Epidemiology, and End Results analysis. *Cancer*. 2014; 120:3707-3716.
 34. McGlashan ND, Harrington JS, Chelkowska E. Changes in the geographical and temporal patterns of cancer incidence among Black gold miners in South Africa. 1964-1996. *Br J Cancer*. 2003; 6:1361-9.
 35. Kew MC. Chronic hepatitis B virus infection and hepatocellular carcinoma in Africa. *S Afr J Sci*. 1992; 88: 524-8.
 36. Linsell CA. Liver Cancer and Mycotoxins. In: Williams AO, O' Connor GT, De-The GB, Johnson CA (eds): virus associated cancers in Africa. *IARC Publications*. No. 63. Lyon, France: IARC Press; 1984: 161-5.
 37. Kew MC. Synergistic interaction between aflatoxin B1 and hepatitis B virus in hepatocarcinogenesis. *Liver international*. 2003; 23:405-409.
 38. Makun HA, Anjorin ST, Moronfoye B, Adejo FO, Afolabi OA, Fagbayibo G. Fungal and aflatoxin contamination of some human food commodities in Nigeria. *African Journal of Food Science*. 2010; 4:127-135.
 39. Yu MW, Cheng SW, Lin MW. Androgen receptor gene CAG repeats, plasma testosterone levels, and risk of hepatitis B related hepatocellular carcinoma. *J Natl Cancer Inst*. 2000; 92:2023-2028.
 40. Yu MW, Yang YC, Yang SY. Androgen receptor exon 1 CAG repeats length and risk of hepatocellular carcinoma in women. *Hepatology*. 2002; 36:156-163.
 41. Fernandez E, Gallus S, Bosetti C, Franceschi S, Negri E, La Vecchia C. Hormone Replacement Therapy and cancer risk: a systematic analysis from a network of case-control studies. *Int J Cancer*. 2003; 105:408-412.
 42. Tavani A, Negri E, Parazzini F, Franceschi S, La Vecchia C. Female hormone utilization and risk of hepatocellular carcinoma. *Br J Cancer*. 1993; 67:635-637.
 43. Jaka H, Mshana SE, Ramban PF, Masalu N, Chalya PL, Kalluvya SC. Hepatocellular carcinoma Clinicopathological management in resource-limited setting. *World Journal of Surgical Oncology*. 2014; 12:246.
 44. Seleye-Fubara D, Jebbin NJ. Hepatocellular carcinoma in Port Harcourt, Nigeria. Clinico-Pathologic study of 75 cases. *Ann Afr Med*. 2007; 6: 54-57.
 45. Kemeny F, Vadrot J, Wu A. Morphological and histological features of resected hepatocellular carcinoma in cirrhotic patients in the West. *Hepatology*. 1989; 9:253-7.

46. Cheah PL, Lool LM, Nazarina AR, Goh KL, Rosmawati M, Vijeyasingam R. Histopathological landmarks of hepatocellular carcinoma in Malaysia. *Malaysia Journal of Pathology*. 2003; 25:37-43.
47. Sooklim K, Sriplung H, Piratvisuth T. Histological subtypes of hepatocellular carcinoma in the Southern Thai population. *Asian Pac J Cancer Prev*. 2003; 4:302-306.
48. Bralet MP, Regimbeau JM, Pineau JM, Dubois F. Hepatocellular carcinoma occurring in non-cirrhotic liver. *Epidemiologic and histologic analysis of 80 French cases*. 2000; 32:200-204.
49. Khan M, Haq SA, Ahmed N, Martin MA. Hepatocellular carcinoma in Bangladesh. *Bangladesh Med Res Counc Bulletin*. 1997; 23:16-24.
50. Nzeako UC, Goodman ZD, Ishak KG. Hepatocellular carcinoma in cirrhotic and non-cirrhotic livers. A clinicohistopathologic study of 804 North American patients. *Am J Clin Pathol*. 1996; 105:65-75.
51. El-Serag HB, Davila JA. Is fibrolamellar carcinoma different from hepatocellular carcinoma? A US population based study. *Hepatology*. 2004; 39:798-803.
52. Jernigan PL, Wima K, Hanseman DJ, Hoehn RS, Ahmad SA, Shah SA, Abbott DE. Natural History and Treatment Trends in Hepatocellular Carcinoma Subtypes: Insights From a National Cancer Registry. *Journal of Surgical Oncology*. 2015; 112:872-876.
53. Eggert T, McGlynn KA, Duffy A. Fibrolamellar hepatocellular carcinoma in the USA, 2000-2010: A detailed report on frequency, treatment, and outcome based on the Surveillance, Epidemiology, and End Results database. *United European Gastroenterol J*. 2013; 1:351-357.
54. Sergi C. Fibrolamellar carcinoma: A distinct variant of hepatocellular carcinoma that is still surrounded by unexplained mysteries. *Journal of Cancer Therapy*. 2014; 5:1325-1331.
55. Mayo SC, Mavros MN, Nathan H. Treatment and prognosis of patients with fibrolamellar hepatocellular carcinoma: A national perspective. *J Am Coll Surg*. 2014; 218:196-205.
56. Chedid A, Ryan LM, Dagal Y, Wolf BC, Fackson G. Morphology and other prognostic factors of hepatocellular carcinoma. *Arc Patho Lab Med*. 1999; 123:524-528.